

**PATIENT**

Kiki Simpson

**SPECIES**

Canine

**BREED**

Greyhound

**SEX**

Female Spayed

**PRESENTING CLINICAL SIGNS**

History: New heart murmur, grade 3/6. Exercise intolerance.

**RADIOGRAPHIC FINDINGS** \*NOTE: Images submitted for supplemental cardiac information only.  
Normal cardiac silhouette. No obvious evidence of CHF.

**ECHOCARDIOGRAM FINDINGS**

2D, m-mode, color flow and doppler imaging is available. Minimal diffuse thickening of mitral valve leaflets with no obvious prolapse into the left atrial lumen. Trace central mitral regurgitation is identified. Normal left atrial dimension. Normal LV diameter with adequate myocardial function. The tricuspid valve appears subjectively normal, with no tricuspid regurgitation. The right heart is normal (subjective). No overt evidence of pulmonary arterial hypertension. The pulmonic and aortic valves are normal in morphology and mobility. No aortic abnormalities identified, however the LVOT velocity is mildly elevated. Normal pulmonic outflow velocities. Trace aortic and pulmonic insufficiency. No pericardial or pleural effusion noted. No cardiac tumors observed.

**CARDIAC CHART**

CANINE CARDIAC PARAMETERS	MR VMAX (m/s)	TR VMAX (m/s)	LA/AO (Boon method)	LA/AO (Heart Base; Swe)	FS (%)	EF (%)	EPSS (cm)
NORMAL PARAMETER	4.5-5.5	<2.7	1.3	<1.6	28-40	40-100	<0.6
PATIENT	NM	NA	NM	1.2	29	52	NM
CANINE CARDIAC PARAMETERS	HR (BPM)	AV VMAX (m/s)	PV MAX (m/s)	BODY WEIGHT (kg)	LA 2D short axis Base view (cm)	LVIDd Avg; 2D and m-mode short axis (cm)	LVIDs Avg; 2D and m-mode short axis (cm)
NORMAL PARAMETER	50-100	0.7-1.7	0.7-1.6	BELOW	BELOW	BELOW	BELOW
PATIENT	NM	2.0	0.75	36.3	3.5	5.1	5.6
*Normal chamber parameters expressed as a mean value (SD)				3	1.27 (5.3)	2.46 (2.46)	1.36 (5.5)
<b>BODY WEIGHT DEPENDENT PARAMETERS</b>				5	1.40 (4.5)	2.74 (5.2)	1.60 (4.7)
<i>*Note: All measurements based upon multi-modal images and methods. An average value is reported.</i>				10	1.50 (3.8)	3.27 (3.5)	2.06 (3.1)
				15	1.83 (2.0)	3.71 (2.4)	2.43 (2.1)
				20	2.02 (1.9)	4.14 (2.2)	2.80 (2.0)
				25	2.18 (2.4)	4.48 (2.9)	3.10 (2.5)
				30	2.33 (3.3)	4.83 (3.9)	3.39 (3.4)
				35	2.48 (4.3)	5.17 (5.0)	3.69 (4.5)
				40	2.62 (5.2)	5.48 (6.1)	3.96 (5.4)
				50	2.88 (7.1)	6.07 (8.3)	4.46 (7.4)

**INTERPRETATION OF THE FINDINGS & FURTHER RECOMMENDATIONS**

The only cause of a murmur identified is increased flow velocity through the LVOT/aortic root. Trace MR is noted, which is unlikely to be heard on exam and follow up is advised to screen for progression. No obvious subaortic ridge or valvular abnormalities are visualized, and in the absence of structural abnormalities this is considered a benign flow murmur. If this is a new murmur, it is reasonable to monitor periodically via recheck echocardiography in the future. Additionally screening for fluid status abnormalities (dehydration, anemia, etc.) is recommended through routine lab work as these abnormalities would make this finding more prevalent. A small

**REFERRING VET**

Dr. Fitz

**INVOICE**

25274

**DATE**

7/12/22

**INTERPRETED BY**

Maggie Machen Lamy, DVM, DACVIM (Cardiology)

**IMAGING PERFORMED BY**

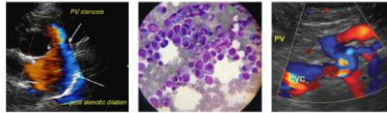
Amy Mayhew, LVT

**HOSPITAL NAME**

SVS Imaging MI

**IMAGING PERFORMED BY**

svsmobileimaging.com 309-737-3070



**PATIENT**

Kiki Simpson

aortic leak is noted, and a baseline blood pressure is recommended. No additional issues are identified.

**SPECIES**

Canine

No cardiac medications are indicated. No cardiac contraindication for general anesthesia.

**BREED**

Greyhound

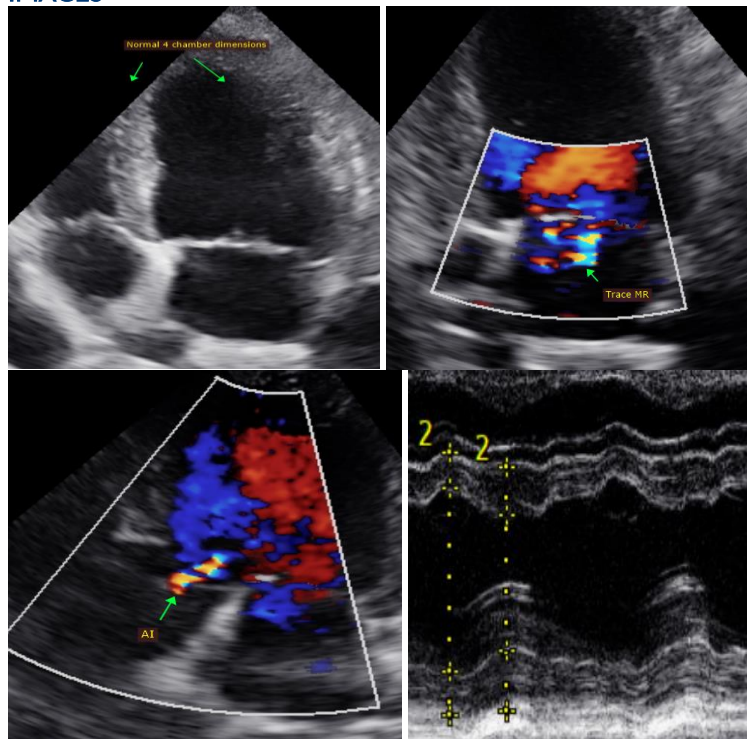
Monitor for any development of cough, labored breathing or exercise intolerance.

Recommend recheck echocardiogram in 12-18 months to screen for progression or development of concurrent cardiac disease that the preexisting murmur may mask.

**SEX**

Female Spayed

**IMAGES**



**AGE**

9 years

**WEIGHT**

80lbs

**INTERPRETED BY**

Maggie Machen Lamy, DVM, DACVIM (Cardiology)

**IMAGING PERFORMED BY**

Amy Mayhew, LVT

The information and recommendations provided are based on the images presented by the referring veterinarian. No evaluation can be communicated regarding pathology that was not visible in the image/video clips provided.

**HOSPITAL NAME**

SVS Imaging MI

Thank you for this referral. If the clinical or image interpretation does not parallel your findings or if I can be of any further assistance, please contact me.

**REFERRING VET**

Dr. Fitz

Maggie Machen Lamy, DVM  
Diplomate of the American College of Veterinary Internal Medicine (Cardiology)  
info@sonopath.com

**INVOICE**

25274

**DATE**

7/12/22

**IMAGING PERFORMED BY**

svsmobileimaging.com 309-737-3070



EDUCATIONAL TELECONSULTATION SERVICES™

1-800-838-4268 info@sonopath.com SonoPath.com

**PATIENT**

Kiki Simpson

**SPECIES**

Canine

**BREED**

Greyhound

**SEX**

Female Spayed

**AGE**

9 years

**WEIGHT**

80lbs

**INTERPRETED BY**

Maggie Machen Lamy,  
DVM, DACVIM  
(Cardiology)

**IMAGING  
PERFORMED BY**

Amy Mayhew, LVT

**HOSPITAL NAME**

SVS Imaging MI

**REFERRING VET**

Dr. Fitz

**INVOICE**

25274

**DATE**

7/12/22